Surgical Innovation
http://sri.sagepub.com/

Combination of Pseudocontinent Perineal Colostomy and Appendicostomy : A New Approach in the Treatment of Low Rectal Cancer

Rasoul Azizi, Mina Alvandipour, Saeed Shoar and Bahar Mahjoubi

SURG INNOV published online 10 December 2012
DOI: 10.1177/1553350612469280

The online version of this article can be found at:
http://sri.sagepub.com/content/early/2012/12/07/1553350612469280

Published by:
SAGE
http://www.sagepublications.com

On behalf of:
ircad France
Institute for Research into Cancer of the Digestive System

Surgical Innovation
XX(X) 1–7

DOI: 10.1177/1553350612469280
http://sri.sagepub.com
SAGE

Combination of Pseudocontinent Perineal Colostomy and Appendicostomy: A New Approach in the Treatment of Low Rectal Cancer

Rasoul Azizi, MD[1], Mina Alvandipour, MD[1], Saeed Shoar, MD[1,2], and Bahar Mahjoubi, MD[1]

Abstract

Background. Abdominal perineal resection (APR) with applied colostomy remains the standard treatment for low rectal cancer; however, to date, a very high morbidity rate has been reported. *Aims*. The aims of this study were to assess fecal continence, persistence of disease-related symptoms, and quality of life in patients with low rectal cancer after APR and pseudocontinent perineal colostomy and concomitant appendicostomy. *Methods*. We included 17 patients with low rectal cancer who underwent APR at our hospital in this cross-sectional study. Following APR, pseudocontinent perineal colostomy and concomitant appendicostomy were performed. Patients then underwent antegrade colonic enema with tap water. Patients' symptoms, fecal continence, and quality of life were evaluated at regular time intervals. *Results*. After a median follow-up of 12 months, 15 of 17 patients completed the study period. All patients were able to perform an antegrade enema by themselves. Mean continence score was 7 (out of 20) based on the Wexner Scale scoring system. Mean global health status score was 78, physical function was 93, and emotional function was 88. Minor morbidity was observed in 6 patients (40%). *Conclusion*. Pseudocontinent perineal colostomy with appendicostomy provides an acceptable level of continence and functional and emotional improvement in patients with low rectal cancer undergoing APR. Hence, this combinative method could be considered as an alternative for abdominal colostomy in selected patients.

Keywords

abdominal perineal resection, pseudocontinent perineal colostomy, appendicostomy, low rectal cancer

Introduction

Over the past decade, the management of rectal cancer has evolved remarkably. A sphincter-preserving operation is the surgical treatment of choice in upper and middle-rectal cancers.[1] Abdominal perineal resection (APR) is indicated when rectal cancer invades the pelvic floor or anal sphincter or when the patient has insufficient anal sphincter left following sufficient surgical resection. APR has been reported to be mandatory in 10% to 30% of patients with rectal cancer.[2] Despite the oncological benefits of APR, subsequent abdominal colostomy may have a negative effect on quality of life in the majority of these patients.[3] To avoid an abdominal colostomy, many attempts have been made to restore gastrointestinal continuity in patients undergoing APR. To date, several alternatives to permanent abdominal colostomy have been proposed. Perineal colostomy is a safe and functionally acceptable procedure for perineal reconstruction after APR for rectal cancer.[4] There is no additional morbidity related to perineal colostomy, and the procedure is associated with decrease in perineal morbidity and shorter duration of healing.[4] To improve fecal continence after perineal colostomy, pseudocontinent perineal colostomy was introduced by Schmidt and Bruch.[5] They used this technique after performing APR for rectal cancer. The results were satisfying in terms of survival and quality of life.

[1]Rasoul-e-Akram Hospital, Tehran University of Medical Sciences, Tehran, Iran
[2]Shariati Hospital, Tehran University of Medical Sciences, Tehran, Iran

Corresponding Author:
Rasoul Azizi, Department of Colorectal Surgery, Rasoul-e-Akram Hospital, Tehran University of Medical Sciences, Niayesh Street-Sattarkhan Ave, Tehran, Iran
Email: razizimd@hotmail.com

To restore fecal continence after perineal colostomy, pseudocontinence ostomy has been suggested, with reconstruction using smooth musculoplasty.[6-9] A recent study showed that perineal colostomy with spiral smooth muscle graft for neosphincter reconstruction following APR in very-low rectal cancers is a surgical option for a selective group of patients, with reasonable functional long-term results and an improved quality of life.[7] Another study analyzed the oncological and functional outcomes after APR in addition to pseudocontinence perineal colostomy for epidermoid carcinoma of the anus and concluded that this procedure does not compromise the beneficial effect of salvage surgery and is safe and feasible after a high dose of radiotherapy.[10] Patients with a pseudocontinence perineal colostomy need lifetime retrograde colonic irrigation to regulate stool evacuation.[11] Malone and colleagues introduced a method of appendicostomy for antegrade colonic enema (ACE) to improve postoperative continence in children with congenital anorectal malformation, and this procedure resulted in pseudocontinence in 75% of the patients.[12,13] Using Malone ACE in patients with perineal colostomy after rectal resection has resulted in satisfactory continence and quality of life.[9,14,15]

This study aimed to assess fecal continence, disease-related symptoms, and patients' satisfaction and quality of life in those with pseudocontinent perineal colostomy and appendicostomy after APR for low rectal cancer. In fact, we decided to combine these 2 procedures to achieve a maximum level of continence and secure higher quality of life after performing perineal colostomy in patients with low rectal cancer who had undergone APR. To the best of our knowledge, a combination of these 2 procedures after APR has never been documented.

Patients and Methods

Between 2000 and 2010, 50 patients underwent APR for adenocarcinoma of the distal rectum at a single university-affiliated hospital; of these, 17 ones underwent perineal reconstruction with a pseudocontinent perineal colostomy and concomitant appendicostomy. Inclusion criteria were the presence of confirmed diagnosis of ultralow rectal tumors (by histological pathology and imaging studies) in which performance of a sphincter-saving surgery was not possible. The standard technique was explained to the eligible patients in detail. Patients with mentally disabling conditions, diseases that affect the process of wound healing, medical conditions such as diabetes or malnutrition, and lack of compliance performing enema were excluded. Those patients who did not accept the standard technique of APR and abdominal colostomy were then presented with the new proposed method of APR, which combines perineal colostomy and appendicostomy. All the patients gave informed consent before entering the study, and finally, the Research and Ethics Committee of Tehran University of Medical Sciences in Tehran, Iran, approved the whole study protocol. The researchers were all dedicated to the principles of the Declaration of Helsinki during the whole study period.

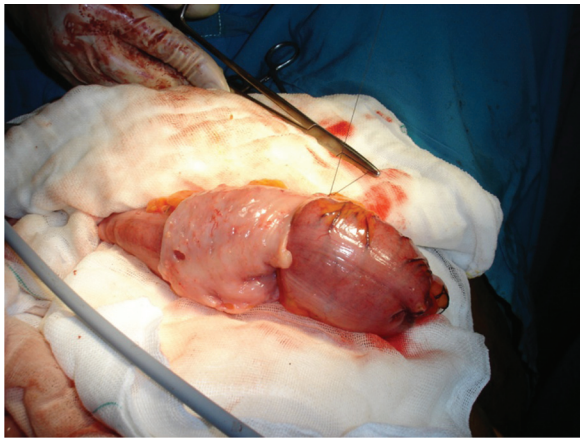

Figure 1. Surgical technique: a free flap obtained from colonic smooth muscle is sutured around the colon, 4 cm proximal to the perineal colostomy

The procedure was completed by construction of an appendicostomy or cecal conduit for antegrade enema. The technique was chosen by the patients after the different surgical techniques and benefits or disadvantages were explained by the expert stoma nurse. The patients who were selected for the study were able to perform lifetime daily colonic irrigation.

Surgical Procedure

The surgery was performed in 2 steps. Primarily, APR was performed with respect to the oncological criteria. Briefly, after mobilization of the descending colon and splenic flexure, the colon was transected at the midportion of the sigmoid colon. After performing the perineal stage of the procedure and removal of the specimen, a 10-cm length of the proximal part of the specimen was resected. Mesenteric fat and epiploic appendages were also removed. After a longitudinal incision along the tenia coli, the graft was stretched, and 10 cc of normal saline was injected into the submucosal layer. This free flap of smooth muscle was stitched around the colon with 3-0 absorbable sutures, 4 cm proximal to the distal colon (Figure 1). Finally, the pull-through colon was sutured to the anal margin without tension using 3-0 absorbable sutures. At the same time, an appendicostomy, a cecal or ileal conduit, was constructed over a small catheter, which was left in place for 1 week. After removing the appendix through the abdominal wall

Figure 2. Skin flap for constructing an appendicostomy with wider lumen

Figure 4. Final view of the appendicostomy

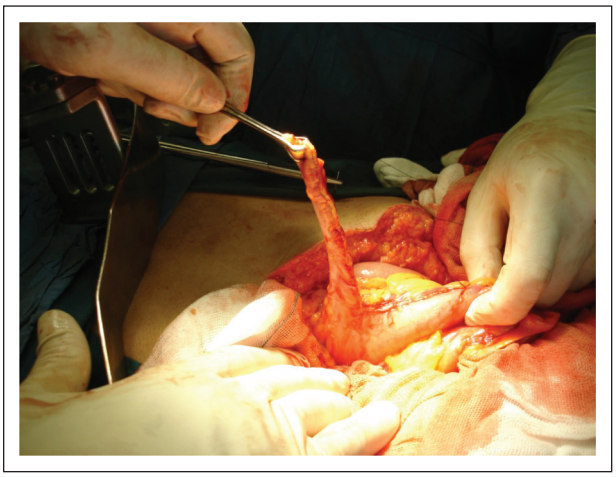

Figure 3. Cecal conduit

and dissecting the appendix longitudinally, a U-shaped skin flap was attached to the wall of the appendix in a cross-sectional direction and then sutured to the antimesenteric side of the lumen with 4-0 absorbable suture material. The main portion of the lumen was covered by the skin flap to provide a wider passage for insertion of the irrigating catheter (Figures 2-4). It was suggested that antegrade enema be started 1 week after the operation, using 1000 cc of tap water. An expert stoma nurse trained the patient to perform ACE and self-catheterization at an outpatient setting.

Follow-up and Measurement of Outcomes

Patients were visited regularly at 3, 6, and 12 months postoperatively, and then, annual visits were arranged if regular follow-ups retrieved no major concerns. Clinical examination and a face-to-face survey aimed to evaluate the function of appendicostomy and perineal colostomy, aiming to detect any surgical complication or dysfunction of ostomy. Functional assessment was performed in our outpatient clinic by using the functional questionnaire EORTC QLQ-C 30. The questionnaire consisted of 30 items, corresponding to 6 multi-item function scales measuring physical, role, social, emotional, and cognitive functions and the patient's overall health status. Scores of these multi-item scales were linearly transformed to a scale from 0 to 100. Zero corresponds with the worst- and 100 with the best-functioning scale. Conversely, 0 denotes the best and 100 the worst on the scaling system. Hence higher scores represented better functioning but more symptoms and vice versa.[16,17] The incontinence status was also assessed by the expert surgeon and scored based on the Wexner Scoring Scale.[18]

Statistical analysis was performed using Statistical Package for Social Sciences (SPSS version 16, SPSS Inc, Chicago, IL), and values are presented as number (%).

Results

Of 17 patients initially included in the study, 2 did not succeed in completing the follow-up during the first year and were therefore excluded from the study. The remaining 15 comprised 7 women (46.66%) and 8 men (53.33%). The median age at the time of surgery was 46 years. The mean ± standard deviation of operation time was 240 ± 40 minutes. Neoadjuvant chemoradiotherapy was performed in 12 patients (80%) before the surgery, whereas the remaining 3 patients (20%) were referred for chemoradiation courses 4 weeks after hospital

Table 1. Demographic, surgical, and clinical characteristics of patients

	Measure
Median and range of age (years)	46 (34-71)
Sex (Female/Male)	7/8
Preoperative neoadjuvant chemoradiotherapy	12
Mean ± SD time of operation (minutes)	240 ± 40
Pathology report	
Adenocarcinoma	15
Tumor staging	
PT1	0
PT2	3
PT3/4	12
Nodal staging	
PN0	6
PN1	5
PN2	4
PN3	0
Conduit for antegrade enema	
Appendicostomy	9
Ileal conduit	2
Cecal conduit	4

Abbreviation: SD, standard deviation.

discharge. We constructed an appendicostomy for 9 patients (60%), a cecal conduit in 4 patients (26.66%), and an ileal conduit in 2 patients (13.33%). Patients were followed for a median of 35 months (range between 12 and 96 months; Table 1).

Early complications related to appendicostomy were bleeding at the orifice (n = 2), skin reaction (n = 1), and discharge from the orifice (n = 4), all of which needed no intervention. There was no appendix necrosis or retraction. There was 1 case of abdominal wound infection and 1 case of coloperineal wound infection, which were treated with local wound care. Perineal stoma complication was observed in 2 cases as prolapse of stoma. Late morbidity was reported in 1 case of stricture of the appendicostomy site. After education by the stoma nurse within 10 days of hospital stay, all the patients were capable of using appendicostomy to perform antegrade enema by themselves (Table 2).

Antegrade colonic irrigation was done every day in 7 patients and every other day in the remaining 8, ensuring adequate evacuation of the colon. The volume of water instilled into the cecum varied from 1500 to 2000 cc. Physical examination confirmed palpation of a sphincter-like muscle ring in 15 patients. After a minimum duration of 1 year of follow-up, the mean Wexner incontinence score was 7 among the study participants. Our patients reported a median global health status score of 78. Moreover, all patients completed the European Organisation for Research and Treatment of Cancer quality-of-life (EORTC QLQ-C30) questionnaire. Scores for the EORTC QLQ-C30 are summarized in Table 3.

Table 2. Procedure-related complications

Complications	n (%)
Procedure-related complications	
Abdominal wound infection	1/15 (6.6)
Perineal wound infection	1/15 (6.6)
Appendicostomy-related complications	
Bleeding	2/15 (13.2)
Skin reaction	1/15 (6.6)
Discharge	4/15 (26.4)
Stricture	1/15 (6.6)
Perineal colostomy-related complications	
Prolapse	2/15 (13.2)

Table 3. EORTC QLQ-C30 score (n = 15)

	median score (Range)
Global health status	78 (67-91)
Physical function	93 (65-100)
Role function	100 (60-100)
Emotional function	88 (60-95)
Cognitive function	100 (85-100)
Social function	65 (50-80)
Fatigue	14 (0-60)
Nausea/Vomiting	0 (0-30)
Pain	0 (0-40)
Dyspnea	0 (0-20)
Sleep disturbances	0 (0-60)
Appetite loss	0 (0-55)
Constipation	0 (0-45)
Diarrhea	0
Financial worries	0

Abbreviation: EORTC QLQ-C30, European Organisation for Research and Treatment of Cancer quality-of-life.

Discussion

Despite advances in surgical techniques for rectal cancers during the past years, APR remains the sole applicable procedure in 10% to 30% of patients with low rectal cancers.[2] APR and colostomy are disabling procedures because of the altered body image, problems with stoma appliance, and a high rate of perineal wound complications. Because of these concerns and social and cultural limitations, many patients do not accept this surgery and also refuse to undergo any curative procedure that

results in a permanent colostomy on their abdominal wall. Perineal colostomy as already described by Gamagami et al[9] is not associated with altered body image; however, functional results have not been satisfactory in the patients studied. Perineal colostomy has the benefit of reducing perineal morbidity without causing additional specific morbidity in patients undergoing neoadjuvant radiotherapy.[5] Several studies have been conducted to assess improved functional outcomes after perineal colostomy. Schmidt[15] placed intestinal smooth muscle cuffs in 137 patients to secure a continent abdominal wall colostomy. They reported an 82.2% continence rate, with no necessity for permanent stoma appliance. Gamagami et al have used free colonic muscle grafts for perineal colostomy and reported continence in 59% of the patients. Our technique to use a free flap was adopted from their concept. It should be noted, however, that in their study, a retrograde irrigation was performed,[9] whereas in our patients, antegrade irrigation was preferred because of its feasibility, physiological similarity with normal defecation, and probably minimal interference with patients' daily functions and need for assistance. Cavina[19] transferred the gracilis muscle for neosphincter reconstruction and demonstrated continence in up to 73% of their patients after continuous electrostimulation. Construction of a neosphincter with dynamic graciloplasty has been evaluated after APR in a small series of patients. Functional outcomes of dynamic graciloplasty have not been satisfactory, with frequent difficulties in evacuation, requiring rectal irrigation. Hirche et al[7] have reported the application of spiral smooth muscle grafts for neosphincter reconstruction following APR for very-low rectal cancer and demonstrated an acceptable result with above-average scores in both the global health status and disease-specific questionnaires; 80% of their patients remained continent.

Goere et al[10] showed that pseudocontinent perineal colostomy improves perineal healing and provides a high degree of patient satisfaction. However, with a pseudocontinent perineal colostomy, continence is restored by performing retrograde bowel irrigation every 24 to 48 hours and by implanting a muscle graft around the bowel. Despite implementing these new techniques, enema remains necessary to avoid fecal impaction.

To date, different methods have been applied to reconstruct the anal neosphincter, including implanting artificial sphincters,[20] reconstruction by graciloplasty,[21] and application of electrostimulation as modified dynamic plasty.[22,23] However, the skeletal fibers of the gracilis muscle are not capable of maintaining permanent continence, and associated morbidity has been reported to be high.[24] In contrast, the colonic smooth muscle autotransplant has been preferred as the ideal technique for neosphincter reconstruction because of continuous contraction of type I and II fibrils, providing permanent continence.[5,25,26] Depending on the initial surgical approach for resection of rectal tumors, the site of the reconstructed neosphincter will differ, with the stoma standing on the abdominal wall in Miles and Schmidt's techniques[5,15,24] and perineal colostomy in our method, in accordance with some of the other studies.[25,26] However, existing data regarding long-term functional outcomes and patients' quality of life are limited.

Antegrade enema through a Malone orifice allows colonic evacuation. This technique, as described by Malone, is efficient in children with neurological diseases such as spina bifida and anorectal malformations.[11,27-29] Also, the procedure has been described in the treatment of posttraumatic or neurological incontinence in adult patients.[30-33] Portier et al[12] showed that Malone antegrade continence enema associated with perineal colostomy provides an acceptable level of continence. It preserved the patient's body image and resulted in a satisfying quality of life. With retrograde enema, continence was obtained in 75% of the cases versus 87% with antegrade enema.[30] Farroni et al[8] showed that perineal colostomy in adjunction with appendicostomy or cecal conduit is a valid and acceptable alternative to a perineal colostomy alone. The patients would experience a better functional status and fewer symptoms compared with patients with abdominal colostomy. In our study, we combined these 2 methods to achieve the maximum continence and quality of life after APR for low rectal cancer. We evaluated functional status, persistence of symptoms, quality of life, and continence scores in patients after APR with pseudocontinent perineal colostomy with appendicostomy for ACE. The surgical technique is simple, with minimal prolongation of operating time. We used cecal or ileal conduits in cases of previous appendectomy in patients in whom no appendix remained. However, because of the preserved site of ostoma, function and feasibility of the conduits did not differ significantly, and interpretation of our results is minimally impaired. This was confirmed by similar outcomes for these patients with cecal or ileal conduits compared with patients who underwent appendicostomy.

Early complications with the procedure occurred in nearly 40% of our patients, but all of them were minor, well tolerated, and improved without any major intervention. Late complications included stenosis of appendix stoma, which occurred in 1 patient and was treated with stricturoplasty. The low rate of stricture was a result of the use of the skin flap in appendicostomies to widen the lumen of the appendicostomy to allow easier ACE. Furthermore, sever prolapse occurred in 2 patients in the eighth year of follow-up, which were treated with surgical intervention. Overall quality of life was good in our patients because the scores were $\geq$70 on a scale of 0 to 100.

The mean continence score was 7 after 1 year of follow-up. This indicates that pseudocontinent perineal colostomy with ACE could be considered as a feasible alternative for abdominal colostomy.

The relatively small sample size as a result of the selection criteria for this novel technique compared with the total number of patients undergoing APR during a 10-year period of application of this combinative surgical approach was a limitation of the current study. Furthermore, despite a minimum follow-up of 12 months, it is relatively short in some of our patients for such a complex procedure and may be considered as another limitation of this study. However, early complications, including infection or neosphincter dysfunction, could occur within this short postoperative period. Future studies are needed to objectively investigate patients' quality of life, occurrence of late complications, or colostomy failure. Moreover, manometry should also be used to quantify the level of pressure and stricture in the reconstructed fecal passway.

Conclusion

As the results of this study suggest, a combination of pseudocontinent perineal colostomy with appendicostomy and then ACE for low rectal cancer can improve self-perceived health, continence, and quality of life. The patients seem to have few symptoms related to the procedure. The procedure is safe and involves a simple technique, making it a proper alternative to abdominal colostomy in selected patients, and results in satisfactory continence and quality of life after APR.

Declaration of Conflicting Interests

The author(s) declared no potential conflicts of interest with respect to the research, authorship, and/or publication of this article.

Funding

The author(s) received no financial support for the research, authorship, and/or publication of this article.

References

1. Di Betta E, D'Hoore A, Filez L, Penninckx F. Sphincter saving rectum resection is the standard procedure for low rectal cancer. *Int J Colorectal Dis*. 2003;18:463-469.
2. Tilney HS, Heriot AG, Purkayastha S, et al. A national perspective on the decline of abdominoperineal resection for rectal cancer. *Ann Surg*. 2008;247:77-84.
3. Pachler J, Wille-Jorgensen P. Quality of life after rectal resection for cancer, with or without permanent colostomy. *Cochrane Database Syst Rev*. 2005;(2):CD004323.
4. Kirzin S, Lazorthes F, Nouaille de Gorce H, Rives M, Guimbaud R, Portier G. Benefits of perineal colostomy on perineal morbidity after abdominoperineal resection. *Dis Colon Rectum*. 2010;53:1265-1271.
5. Schmidt E, Bruch HP. Autotransplantation of smooth muscle for treating incontinence of sphincters [in French]. *J Chir (Paris)*. 1981;118:315-320.
6. Lasser P, Dube P, Guillot JM, Elias D. Pseudocontinent perineal colostomy following abdominoperineal resection: technique and findings in 49 patients. *Eur J Surg Oncol*. 2001;27:49-53.
7. Hirche C, Mrak K, Kneif S, et al. Perineal colostomy with spiral smooth muscle graft for neosphincter reconstruction following abdominoperineal resection of very low rectal cancer: long-term outcome. *Dis Colon Rectum*. 2010;53:1272-1279.
8. Farroni N, Van den Bosch A, Haustermans K, et al. Perineal colostomy with appendicostomy as an alternative for an abdominal colostomy: symptoms, functional status, quality of life, and perceived health. *Dis Colon Rectum*. 2007;50:817-824.
9. Gamagami RA, Chiotasso P, Lazorthes F. Continent perineal colostomy after abdominoperineal resection: outcome after 63 cases. *Dis Colon Rectum*. 1999;42:626-630; discussion 30-31.
10. Goere D, Bonnet S, Pocard M, Deutsch E, Lasser P, Elias D. Oncologic and functional results after abdominoperineal resection plus pseudocontinent perineal colostomy for epidermoid carcinoma of the anus. *Dis Colon Rectum*. 2009;52:958-963.
11. Koyle MA, Kaji DM, Duque M, Wild J, Galansky SH. The Malone antegrade continence enema for neurogenic and structural fecal incontinence and constipation. *J Urol*. 1995;154(2, pt 2):759-761.
12. Portier G, Bonhomme N, Platonoff I, Lazorthes F. Use of Malone antegrade continence enema in patients with perineal colostomy after rectal resection. *Dis Colon Rectum*. 2005;48:499-503.
13. Penninckx F, D'Hoore A, Vanden Bosch A. Perineal colostomy with antegrade continence enemas as an alternative after abdominoperineal resection for low rectal cancer [in French]. *Ann Chir*. 2005;130:327-330.
14. Schmidt E. The continent colostomy. World J Surg. 1982 Nov;6(6):805-9.
15. Schmidt E. Plastic surgery for sphincter continence [in German]. *Dtsch Med Wochenschr*. 1981;106:12-14.
16. Aaronson NK, Ahmedzai S, Bergman B, et al. The European Organization for Research and Treatment of Cancer QLQ-C30: a quality-of-life instrument for use in international clinical trials in oncology. *J Natl Cancer Inst*. 1993;85:365-376.
17. Fayers PM, Aaronson NK, Bjordal K, Grønvold M, Curran D, Bottomley A. *EORTC QLQ-C30 Scoring Manual*. Brussels, Belgium: European Organisation for Research and Treatment of Cancer; 2001.
18. Jorge JM, Wexner SD. Etiology and management of fecal incontinence. *Dis Colon Rectum*. 1993;36:77-97.

19. Cavina E. Outcome of restorative perineal graciloplasty with simultaneous excision of the anus and rectum for cancer: a ten-year experience with 81 patients. *Dis Colon Rectum*. 1996;39:182-190.
20. Romano G, La Torre F, Cutini G, Bianco F, Esposito P, Montori A. Total anorectal reconstruction with the artificial bowel sphincter: report of eight cases. A quality-of-life assessment. *Dis Colon Rectum*. 2003;46:730-734.
21. Pickrell KL, Broadbent TR, Masters FW, Metzger JT. Construction of a rectal sphincter and restoration of anal continence by transplanting the gracilis muscle: a report of four cases in children. *Ann Surg*. 1952;135:853-862.
22. Altomare DF, Rinaldi M, Pannarale OC, Memeo V. Electrostimulated gracilis neosphincter for faecal incontinence and in total anorectal reconstruction: still an experimental procedure? *Int J Colorectal Dis*. 1997;12:308-312.
23. Cavina E, Seccia M, Banti P, Zocco G. Anorectal reconstruction after abdominoperineal resection: experience with double-wrap graciloplasty supported by low-frequency electrostimulation. *Dis Colon Rectum*. 1998;41:1010-1016.
24. Rongen MJ, Dekker FA, Geerdes BP, Heineman E, Baeten CG. Secondary coloperineal pull-through and double dynamic graciloplasty after Miles resection: feasible, but with a high morbidity. *Dis Colon Rectum*. 1999;42:776-780; discussion 81.
25. Federov VD, Odaryuk TS, Shelygin YA, Tsarkov PV, Frolov SA. Method of creation of a smooth-muscle cuff at the site of the perineal colostomy after extirpation of the rectum. *Dis Colon Rectum*. 1989;32:562-566.
26. Schlag PM, Slisow W, Moesta KT. Seromuscular spiral cuff perineal colostomy: an alternative to abdominal wall colostomy after abdominoperineal excision for rectal cancer. *Recent Results Cancer Res*. 1998;146:95-103.
27. Curry JI, Osborne A, Malone PS. The MACE procedure: experience in the United Kingdom. *J Pediatr Surg*. 1999;34:338-340.
28. Ellsworth PI, Webb HW, Crump JM, Barraza MA, Stevens PS, Mesrobian HG. The Malone antegrade colonic enema enhances the quality of life in children undergoing urological incontinence procedures. *J Urol*. 1996;155:1416-1418.
29. Goepel M, Sperling H, Stohrer M, Otto T, Rubben H. Management of neurogenic fecal incontinence in myelodysplastic children by a modified continent appendiceal stoma and antegrade colonic enema. *Urology*. 1997;49:758-761.
30. Christensen P, Kvitzau B, Krogh K, Buntzen S, Laurberg S. Neurogenic colorectal dysfunction: use of new antegrade and retrograde colonic wash-out methods. *Spinal Cord*. 2000;38:255-261.
31. Krogh K, Laurberg S. Malone antegrade continence enema for faecal incontinence and constipation in adults. *Br J Surg*. 1998;85:974-977.
32. Gerharz EW, Vik V, Webb G, Leaver R, Shah PJ, Woodhouse CR. The value of the MACE (Malone antegrade colonic enema) procedure in adult patients. *J Am Coll Surg*. 1997;185:544-547.
33. Moore EM. Malone antegrade continence enema for faecal incontinence and constipation in adults. *Br J Surg*. 1998;85:1594.